

# QUILTING, AS AN ALTERNATIVE TO NASAL PACKING, OUR EXPERIENCE AT A GOVERNMENT DISTRICT HOSPITAL IN NORTH INDIA

**Authors:** Vertika Tewari \*(1) Jasmeet Kaur (2) Swati Singhal (3) Vibhuti Aggarwal (3)

**Authors Affiliations:** (1) Ex. SR ENT BRD Medical College Gorakhpur (2) HOD Department of ENT (3) Ex SR DDU Hospital New Delhi

## ABSTRACT

We aimed to study the efficacy of transeptal suturing in patients undergoing septoplasty and to compare the surgical outcome and complications of transeptal suturing with nasal packing. We conducted a prospective, comparative, randomized study in Deen Dayal Upadhyaya hospital New Delhi from July 2016 to May 2017. A total of 60 patients with symptomatic Deviated nasal septum within age group of 18 to 60 years were included in our study. All these patients underwent septoplasty and were randomly divided into two groups of nasal packing and transeptal suturing. Patients were interviewed and assessed for nasal pain, nasal bleeding, epiphora, dryness of mouth, sleep disturbances. Mean Pain score using VAS was 8 in nasal packing group and 2.3 in transeptal suturing group in 48 hours observation period, moreover mean score of 8 on VAS was observed during pack removal in nasal packing group. None of the patient in transeptal suturing group underwent nasal bleeding thus none of them required add on nasal packing. 100% patients in medicated gauze nasal packing group presented with epiphora, headache, sleep disturbances, and dryness of mouth in 48 hours observation period, whereas none of the patient in transeptal suturing group presented with such symptom. None of the patient in either group presented with postoperative septal perforation, synechiae formation, crusting, septal haematoma during 1<sup>st</sup> and 4<sup>th</sup> week diagnostic nasal endoscopy. Even with limited

resources of a government district hospital we were able to conclude transeptal suturing as a better and efficient method to minimize the sufferings of patients undergoing septoplasty.

## KEYWORDS

Quilting, Transeptal suturing, Septoplasty.

## INTRODUCTION

Septoplasty is a tissue sparing procedure where symptomatic septal deviation is corrected by minimal resection of cartilage and bone done by "COTTLE'S MAXILLA PREMAXILLA TECHNIQUE". Septum is stabilized post procedure by different methods namely (a) Nasal packing which can be done by medicated gauze piece, paraffin gauze, BIPP, nasal tampon, fibrin glue etc.<sup>1,2</sup> (b) Nasal splints (c) Transeptal suturing or Quilting.<sup>3</sup> Conventionally nasal packing is done after septoplasty. Its advantages are; to approximate septal muco-perichondrial flaps mechanically, to prevent bleeding, to prevent septal haematoma formation, to stabilize the repositioned cartilage and bony septum and to prevent synechiae formation between septum and lateral nasal wall.<sup>4,5,6</sup> Disadvantages of nasal packing are that it inevitably leads to intense pain while packing, with pack in situ and during pack removal.<sup>7,8,9,10</sup> Packing bypasses nasal respiration and respiratory function in the patients with negative impact on quality of sleep. Nasal packing irritates the nasal mucosa and adversely affects mucociliary action. Thus patient can have epiphora, swallowing

---

---

difficulty, dryness of mouth, headache etc.<sup>3</sup> Transseptal suturing instead of nasal packing has advantages that, apart from providing adequate stability to septal flaps, it also has better patient compliance. There is minimal postoperative pain and discomfort and lesser demand for analgesia. There is added advantage that mucociliary activity is preserved and packing dependent reactions are not observed.<sup>3,11,12,13,14</sup>

#### **AIM**

To study the efficacy of transseptal suturing in patients undergoing septoplasty

#### **OBJECTIVES**

- 1) To compare the surgical outcomes of transseptal suturing with nasal packing in patients undergoing septoplasty.
- 2) To compare the complications of transseptal suturing with nasal packing in patients undergoing septoplasty.

#### **MATERIAL AND METHODS**

The present study was conducted in the Department of Otorhinolaryngology in Deen Dayal Upadhyaya Hospital, New Delhi.

#### **STUDY DESIGN**

Prospective, Comparative and Randomised study.

#### **DURATION OF STUDY**

July 2016 to May 2017.

#### **SAMPLE SIZE**

Sample Size was determined based on efficacy of transseptal suturing versus nasal packing in patients undergoing septoplasty (in terms of VAS). With reference to previous study, the mean reported pain was calculated as 2.3 in the Suturing group and 4.8 in the packing group. The total sample size was set as 60 (30 per group) calculated from an effect size of 0.83, a power of 90%, and a  $\alpha$  of 0.05 where the standard deviation of two groups was 3.

#### **STUDY POPULATION**

Patients visiting E.N.T outpatient department were

selected according to inclusion and exclusion criteria.

#### **INCLUSION CRITERIA**

Symptomatic deviated nasal septum above the age of 18 and less than the age of 60 years for both genders.

#### **EXCLUSION CRITERIA**

- 1) History of previous nasal surgery.
- 2) Presence of chronic rhinosinusitis with nasal polyposis.
- 3) Presence of inferior turbinate hypertrophy.
- 4) Uncontrolled Diabetes mellitus.
- 5) Uncontrolled hypertension.
- 6) Blood disorders.
- 7) Patients on anticoagulant therapy.
- 8) Sino nasal neoplasm.

#### **DATA COLLECTION**

After taking detailed medical history and clinical examination, preoperative investigations were done. Informed and written consent was obtained and the patients were posted for Septoplasty. Patients were randomly divided in two groups post operatively.

Group A: Transseptal suture without nasal packing.

Group B: Medicated gauze nasal packing.

Patients of both the groups were kept in post operative observation for 30 minutes with head elevated by 30 degrees thereafter minimum 48 hours of hospital stay for both the groups. Inj Ampicillin, Inj. Paracetamol, Inj Ranitidine and Tab Levocetizine was given to all for 48 hours.. Nasal pack was removed gently after 48 hours. Patients were started with Xylometazoline and Liquid Paraffin nasal drops from the day of surgery in transseptal suturing group and after pack removal in packing group. Nasal douching (with warm water, normal salt and baking soda) was started after 48 hours in patients of both the groups.

#### **METHOD OF SEPTOPLASTY AND TRANSSEPTAL SUTURING/QUILTING**

We performed septoplasty by 'Cottle's maxilla –premaxilla technique' using conventional

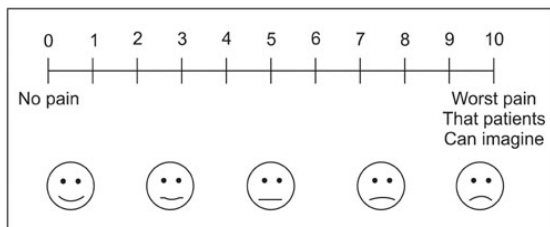
headlight. Quilting was also performed using headlight in the patients randomly selected for the same.

- 1) In this method the septum is quilted with 3-0 vicryl.
- 2) Prior to quilting few knots will be placed at the distal end of suture.
- 3) Shaft of the needle and its natural curve are kept in same plane as handle of needle holder.
- 4) Initial suture is placed in cartilaginous part of the septum just anterior to midpoint of middle turbinate.
- 5) Needle is passed through the septum to opposite side and after few millimeters it is passed again to opposite side through the septum, thus creating a quilting effect.
- 6) Suture is then brought forward to caudal end and stitch is placed so that incision is closed by suture.

#### OUTCOME MEASURES

Patients were interviewed and assessed on first and second post operative day for nasal bleeding, epiphora, headache, sleep disturbances and dryness of mouth. These were reported as present or absent.

Patients were evaluated for nasal pain preoperatively and postoperatively at 24 hours and 48 hours in both the groups and also during pack removal in medicated gauze piece packing group. Visual Analogue Scale was used for pain assessment.



All the patients were followed up on first and fourth post operative week with Diagnostic nasal endoscopic examination and they were assessed for, septal haematoma, synechiae, crust formation and septal perforation.

#### STATISTICAL ANALYSIS

Categorical variables were presented in number and percentage (%) and continuous variables were presented as mean  $\pm$  SD and median. Normality of data was tested by Kolmogorov-Smirnov test. If the normality was rejected then non parametric test was used.

Statistical tests were applied as follows:

All the patients were followed up on first and fourth post operative week with Diagnostic nasal endoscopic examination and they were assessed for, septal haematoma, synechiae, crust formation and septal perforation.

#### STATISTICAL ANALYSIS

Categorical variables were presented in number and percentage (%) and continuous variables were presented as mean  $\pm$  SD and median. Normality of data was tested by Kolmogorov-Smirnov test. If the normality was rejected then non parametric test was used.

Statistical tests were applied as follows-

1. Quantitative variables were compared using Unpaired t-test/Mann-Whitney Test (when the data sets were not normally distributed) between the two groups.
2. Qualitative variables were correlated using Chi-Square test/Fisher's exact test.

A p value of  $<0.05$  was considered statistically significant.

The data was entered in MS EXCEL spreadsheet and analysis was done using Statistical Package for Social Sciences (SPSS) version 21.0.

#### RESULTS NASAL PAIN

In the study mean pain score using VAS during preoperative period was found to be 5 in nasal packing group and 2.07 in transseptal suturing group. Postoperative mean pain score was 8 in nasal packing group whereas it was 2.3 in transseptal suturing group during 48 hours observation period. Moreover mean score of 8

was observed during pack removal in nasal packing group.

**POSTOPERATIVE SYMPTOMATOLOGY**

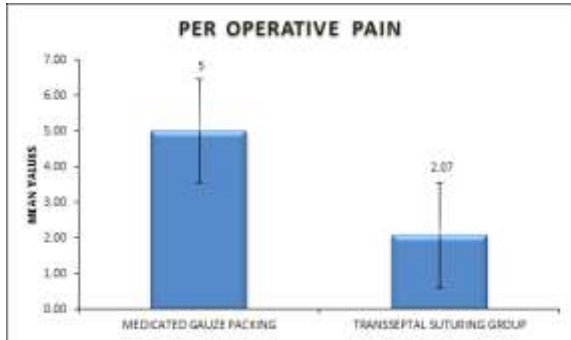
Nasal bleeding, Epiphora, Sleep disturbances, Dryness of mouth, Headache.

In the study all 30 patients(100%) in medicated gauze nasal packing presented with dryness of mouth, epiphora, sleep disturbances, headache whereas none of the patient in transseptal suturing group had similar complaints. No patient of either group presented with nasal bleed, no repacking required in any of 'quilting' group.

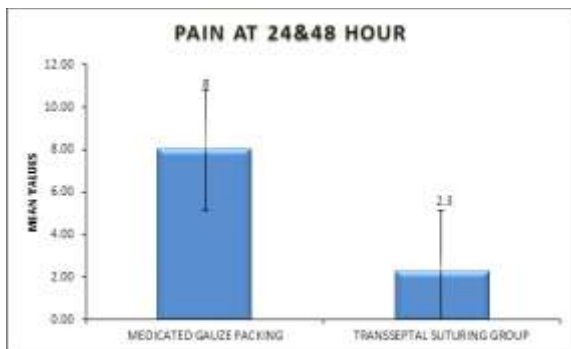
**POSTOPERATIVE DIAGNOSTIC NASAL ENDOSCOPY 1& 4 WEEK**

No patient in any group presented with Septal haematoma, Septal perforation, Crust formation or Synechiae when they were followed up in first and fourth post operative DNE.

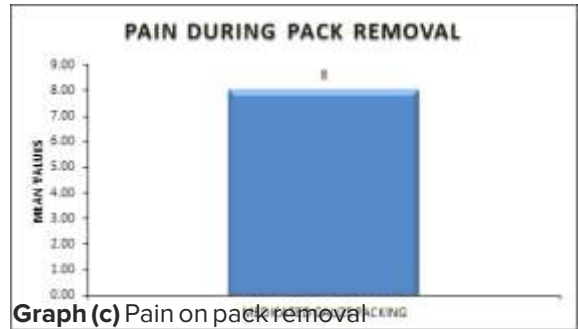
**GRAPHS**



**Graph (a):** Per Operative Pain



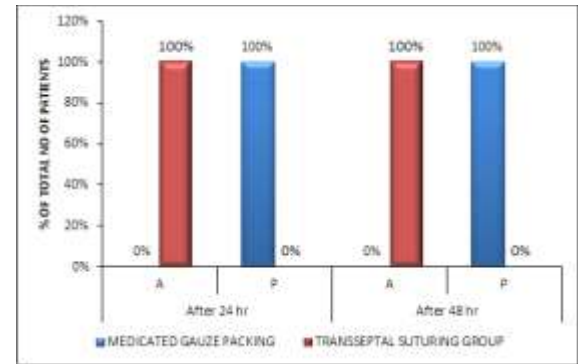
**Graph (b):** Post Operative Pain at 24 & 48 Hrs.



**Graph (c)** Pain on pack removal

**POSTOPERATIVE SYMPTOMATOLOGY**

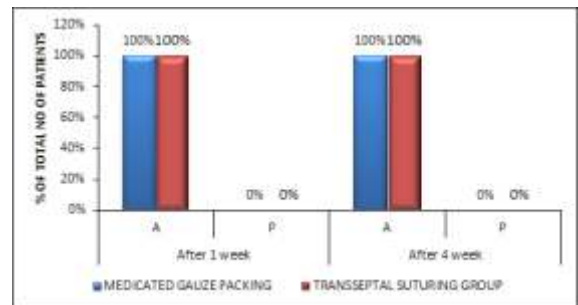
Epiphora, Sleep disturbances, Dryness of mouth:100% patients in packing group presented with these symptoms in 48 hours observation period whereas none of the patient in quilting group had these symptoms.



**Graph (e)** Postoperative nasal bleeding  
No patient in any group presented with postoperative nasal bleeding.

**POSTOPERATIVE DIAGNOSTIC NASAL ENDOSCOPY 1& 4 WEEK**

No patient in any group presented with Septal haematoma, Septal perforation, Excessive Crust formation or Synechiae when they were followed up in first and fourth week post operative DNE.



**Graph (f)** DNE 1<sup>st</sup> & 4<sup>th</sup> week

---

---

## **DISCUSSION**

### **NASAL PAIN**

In the study patients with nasal packing have higher pain score preoperatively (mean of 5 on VAS) and mean of 8 on both 1<sup>st</sup> and 2<sup>nd</sup> postoperative days. An additional mean score of 8 was observed during pack removal in this group. Patients in transseptal suturing group had mean score as 2.07 per-operatively whereas a score of 2.3 on 1<sup>st</sup> and 2<sup>nd</sup> postoperative day. This difference was statistically significant. It is seen because pressure applied by medicated gauze nasal pack on nasal wall, results in more pain sensation. Similar observations were made in previous studies, viz. Curukova et al<sup>3</sup> reported a mean pain score as 4.8 in nasal packing group and 2.3 in transseptal suturing group and this result was statistically significant. Awan et al<sup>15</sup> observed that most common pain score postoperatively was 10 in packing group and 1 in non packing group. Walliker et al<sup>16</sup> in their study found that 79.3% of patients with nasal pack experienced postoperative pain as compared to 25.7% in patients without pack. Naghibzadeh et al<sup>17</sup> mentioned in their study that all patients (n=77) in nasal packing group had severe pain, while only 2 out of 68 patients without nasal pack experienced such pain.

### **POSTOPERATIVE SYMPTOMATOLOGY**

#### **NASAL BLEEDING**

None of the patients in the study had significant nasal bleed requiring packing in transseptal suturing group (only minimal oozing was observed postoperatively) or repacking in nasal packing group. A review of literature corroborates our finding. Ansari et al<sup>12</sup> in their study observed postoperative nasal bleeding in 11.43% (n=8) in the nasal packing group and 7.14% (n=5) in septal suturing group and reported difference as insignificant. Curukova et al<sup>3</sup> in their study found that 4 patients (1.1%) in suturing group and 6 patients (1.8%) in packing group suffered nasal bleeding post septoplasty but the difference was not statistically significant. Said et al<sup>14</sup> in their study, reported no significant difference

in postoperative nasal bleeding among the two groups however patients of nasal packing group experienced mild bleeding at the time of pack removal.

#### **EPIPHORA**

In the study none of the patients in the transseptal suturing group experienced postoperative epiphora whereas, 100% patients in the nasal packing group experienced it. Thus there is statistically significant difference between the two groups. Epiphora occurs due to the excessive pressure of the pack within the nasal cavity which results in obstruction of naso-lacrimal duct and diversion of lacrimal flow outside the nasal cavity. An agreement with our results was observed in previous studies. Awan et al<sup>15</sup> in their study found that all patients 100% in packing group experienced epiphora as compared to 11.4% in transseptal suturing group. Said et al<sup>14</sup> observed that 100% patients in packing group had epiphora as compared to transseptal suturing group where 86% 'did not' develop it. Anand et al<sup>18</sup> in their study, observed that 95% of patients in packing group suffered epiphora when compared to only 5% in the group with septal clips.

#### **HEADACHE**

In the study all the patients with nasal packing experienced headache and required to pup analgesia in the postoperative period. Headache subsided only after pack removal done after 48 hours whereas none of the patients experienced headache in the suturing group neither required top up analgesia. This is because the nasal pack has more mass bulk which causes obstruction of sinus ostia and impaired drainage with stasis of secretion, making patients more prone to headache. Similar observations were made in various previous studies, viz. Awan et al<sup>15</sup> found that 90.9% of patients in packing group experienced postoperative headache as compared to 20.5% of patients in septal suturing group. Walliker et al<sup>16</sup> observed that the majority of packing group patients developed headache 61 out of 77 as compared

---

---

to non packing group where only 19 out of 74 patients had such event. Said et al<sup>14</sup> observed a statistically significant difference between nasal packing and transseptal suturing group with respect to postoperative headache  $p < 0.01$ . Daniel et al<sup>19</sup> observed statistically significant difference between nasal packing and transseptal suturing group in their study  $p < 0.01$ .

### **SLEEP DISTURBANCES**

In the study 100% patients in packing group experienced statistically significant difference in sleep duration and quality when compared to transseptal suturing group. This can be attributed to mechanical obstruction of the airway due to nasal pack along with higher pain level. Nearly similar results were observed while reviewing previous studies, viz. Awan et al<sup>15</sup> observed that 81.1% of patients in packing group had less than 6 hours of sleep on night of surgery compared with only 16.2% in non packing group ( $p < 0.05$ ). Said et al<sup>14</sup> reported a statistically significant difference between nasal packing and transseptal suturing group  $p < 0.001$

### **DRYNESS OF MOUTH**

In the study 100% patients in nasal packing group experienced dryness of mouth when compared to transseptal suturing group where none of the patient had the complaint. Anand et al<sup>19</sup> reported that all 40 patients 100% in nasal packing group experienced dryness of mouth when compared to only 4 patients 10% in group with nasal clip. Not much literature was found while assessing this variable.

### **CONCLUSION**

Present study reveals that transseptal suturing in patients undergoing septoplasty is a beneficial option as the patients were comfortable pre-operatively and postoperatively with minimal pain. Moreover additional disturbing symptoms like headache, epiphora, dryness of mouth, sleep disturbances are negligible. Since no nasal pack or tampons were used the cost of these packing materials along with ointment or cream is eliminated. Also no extra suture is used thus making this procedure cheaper and cost effective. Patients undergoing septoplasty with nasal

packing experienced more pain while packing, with pack in situ and during pack removal. They also experienced all the above mentioned disturbing symptoms up to 48 hours thereby making their life miserable during their stay in the hospital. Transseptal suturing is a tedious procedure for the beginners though can be easily performed with practice. Surgeon should also ensure that the needle does not hit the lateral nasal wall during Quilting so as to prevent synechiae formation and excessive nasal bleeding. Thus it can be concluded that transseptal suturing can be performed in all patients undergoing septoplasty as it is not only a cost effective procedure but also it improves patients' quality of life postoperatively thus making both patient and surgeon comfortable during postoperative period. Taking the benefits into consideration we strongly recommend transseptal suturing to be performed routinely after septoplasty.

### **NASAL ENDOSCOPIC EVALUATION AT 1<sup>ST</sup> AND 4<sup>TH</sup> WEEK POSTOPERATIVELY SEPTAL HAEMATOMA**

None of the patient in the study presented with septal haematoma during follow up. Review of literature holds agreement with our observation. Curukova et al<sup>3</sup> observed no septal haematoma in their study. Ansari et al<sup>13</sup> mentioned in their study report that there were 2 cases of septal haematoma in suturing group and none with this complication in packing group. Rakeshet al<sup>13</sup> observed in their study that 2 patients in transseptal suturing group had septal haematoma whereas none of the patients in packing (nasal tampon or medicated gauze piece) had similar complaints. Said et al<sup>14</sup> did not report any case in either group with septal haematoma.

### **SYNECHIAE**

In our study no patients had synechiae formation as observed during follow up DNE at 1<sup>st</sup> and 4<sup>th</sup> week. Naghibzadehet al<sup>17</sup> presented in their study a statistically non significant risk reduction in synechiae formation in non packing group. Similar results were obtained in the studies of Nunez<sup>9</sup>. Awan et al<sup>15</sup> found in their study a higher rate of synechiae formation in (18.2%) in packing

---

---

group versus 0% in non packing group. Said et al<sup>14</sup> observed synechiae formation in 2 patients in packing group at the time of 4<sup>th</sup> week DNE. It has been observed that nasal packing makes the nasal mucosa raw and thus more susceptible to synechiae formation. Synechiae can be prevented by minimal manipulation of turbinates, carefully handling the septal mucosa and by meticulous use of instruments.

### **CRUST FORMATION**

None of the patient in the study had crust during follow up DNE at 1<sup>st</sup> and 4<sup>th</sup> week as all the patients in the study were advised alkaline nasal douching post operatively. Rakeshet al<sup>13</sup> observed that 10 patients in medicated gauze nasal packing and 2 patients in merocel pack group had crust formation, whereas none in septal suturing group had the complaint. Thapa et al<sup>20</sup> in their study reported crust formation in 3 from 44 patients in suturing group and 9 out of 41 patients in BIPP packed group, and the difference was statistically significant. Said et al<sup>14</sup> mentioned in their study that there were 2 patients with crust formation in suturing group and 4 patients in packing group. This review of previous studies holds true with our finding though a statistically insignificant occurrence of crust formation was seen in either of the group.

### **SEPTAL PERFORATION**

In current study septal perforation was not reported in any case postoperatively. Studies done by Kula<sup>21</sup>, Naghibzadeh<sup>17</sup>, Gunaydin<sup>22</sup> showed similar results. Curukova et al<sup>4</sup> reported that 8 cases (2.2%) in suturing group and 11 cases (3.2%) in packing group presented with postoperative septal perforation but this result was statistically not significant. No case of septal perforation was reported by Said et al<sup>15</sup>, which corroborates with our finding.

### **CONCLUSION**

Present study reveals that transseptal suturing in patients undergoing septoplasty is a beneficial option as the patients were comfortable per-operatively and postoperatively with minimal pain. Moreover additional disturbing symptoms like headache,

epiphora, dryness of mouth, sleep disturbances are negligible. Since no nasal pack or tampons were used the cost of these packing materials along with ointment or cream is eliminated. Also no extra suture is used thus making this procedure cheaper and cost effective. Patients undergoing septoplasty with nasal packing experienced more pain while packing, with pack in situ and during pack removal. They also experienced all the above mentioned disturbing symptoms up to 48 hours thereby making their life miserable during their stay in the hospital. Transseptal suturing is a tedious procedure for the beginners though can be easily performed with practice. Surgeon should also ensure that the needle does not hit the lateral nasal wall during quilting so as to prevent synechiae formation and excessive nasal bleeding. Thus it can be concluded that transseptal suturing can be performed in all patients undergoing septoplasty as it is not only a cost effective procedure but also it improves patients' quality of life postoperatively thus making both patient and surgeon comfortable during postoperative period. Taking the benefits into consideration we strongly recommend transseptal suturing to be performed routinely after septoplasty.

### **REFERENCES**

1. Kumar A, Omar B, Aja N. Double blind randomised controlled trial comparing merocel with rapid rhino nasal packs after routine nasal surgery. *Rhinology*. 2003; 41:241-243.
2. Daneshrad P, Chingregory Y, Ricedale H. Fibrin glue prevents complications of septal surgery: findings in a series of 100 patients. *Ear Nose Throat J*. 2003;82:196-198.
3. Curukova EA, Cetinkayal GC. Retrospective analysis of 697 septoplasty surgery cases: packing versus transseptal suturing method. *Acta Otorhinolaryngol Ital*. 2012;89:53-58.
4. Laing MR, Clark LJ. Analgesia and removal of nasal packing. *Clin Otolaryngol Allied Sci*. 1990;15:339-342.
5. El-Silimy O. Inferior turbinate reduction the

- need of a nasal pack. *J Laryngol Otol.* 1993;107:906-907.
6. Watson MG, Campbell IJB, Shonai PM. Nasal surgery; does the type of nasal pack influence the results? *Rhinology.* 1989; 27: 105-111.
  7. Fairbanks DNF. Complications of nasal packing. *Otolaryngol Head Neck Surg.* 1986;94:412-415.
  8. Von S M, Robinson P, Ryan R. Nasal packing after routine nasal surgery – is it justified? *J Laryngol Otol.* 1998;107:902-905.
  9. Nunez DA, Martin FW. An evaluation of post operative packing in nasal septal surgery. *Clin Otolaryngol.* 1991;16: 549-550.
  10. Illium P, Grymer L, Hilberg O. Nasal packing after septoplasty. *Clin Otolaryngol.* 1992.; 17:158-162.
  11. Lemmens W, Lemkens P. Septal suturing following nasal septoplasty, a valid alternative for nasal packing? *Acta Otolaryngol.* 2001;55(3): 215-221.
  12. Ansari MA, Umaraimull, Hirani I et al. Transseptal suturing technique without intranasal packing in nasal septal surgery. *Pak J Surg.* 2013;29(2):123-126.
  13. Rakesh S, Amit M. Septoplasty: postoperative alternative for control of haemorrhage and discomfort. *Sch J App Med Sci.* 2014;2(4D): 1376-1380.
  14. Said MS, Abubakir FA. Effect of transseptal suture technique versus nasal packing after septoplasty. *IJTRA.* 2015;3(4):33-40.
  15. Awan MS, Iqbal M. Nasal packing after septoplasty: a randomised comparison of packing versus no packing in 88 patients. *Ear Nose Throat J.* 2008;87(11):624-627.
  16. Walliker BN, Rashikar SM, Fathima AK, Watwe MV, Kakkeri A. A comparative study of septoplasty with or without nasal packing. *Indian J Otolaryngol Head Neck Surg.* 2011;63(3):27-48.
  17. Naghibzadeh B, Peyvandi AA, Naghibzadeh G. Does post septoplasty nasal packing reduce complications? *Acta Med Iran.* 2011;49(1):9-12.
  18. Velusamy A, Handa S, Shivasamy S. Nasal septal clips: an alternative to nasal packing after septal surgery. *Indian J Otolaryngol Head Neck Surg.* 2012;64(4):346-350. doi:10.1007/s12070-011-0388-2.
  19. Daniel P, Juan CF, Silvia BB et al. Transseptal suturing, a cost effective alternative for nasal packing in septal surgery. *Braz J Otolaryngol.* 2016;82(3):310-313. doi:10.1016/j.bjorl.2015.05.016.
  20. Shah S, Kumari S, Pradhan B, Thapa N. Outcomes of endoscopic quilting of nasal septum versus nasal packing following septoplasty. *IJORL.* 2010;13:1-5.
  21. Kula M, Yucel, Unlu Y, Tutus A, Cagli S, Ketencil. Effect of nasal packing and haemostatic septal suture on mucociliary action after septoplasty: an assessment by rhinoscintigraphy. *Eur Arch Otorhinolaryngol.* 2010;267(4):541-546.
  22. Gunaydin RO, Aygenc E, Karakullukcu S, Fidan F, Kashmiri ZA. Nasal packing and transseptal suturing techniques: surgical and anaesthetic perspectives. *Eur Arch Otorhinolaryngol.* 2011;268:1151-1156.

**\*Corresponding author**

Vertika Tewari  
 (MBBS DLO DNB (DDU Hospital New Delhi)  
 Email: vrtsmbe26@gmail.com  
 Phone 8130728531  
 Orchid id; 0000-0002-5362-3506  
 Address: Pitambra Niwas, Shivpuri, Sector 3,  
 Near Fatima Hospital Padre Bazar, Gorakhpur  
 UP.273014

**How to Cite the article**

Vertika Tewari et al, Quilting, As An Alternative To Nasal Packing, Our Experience At A Government District Hospital In North India, *UPJOHNS* June 2022; 10(1) - 27-35 DOI: <http://doi.org/10.36611/upjohns/volume10/Issue1/>



This work is licensed under a Creative Commons Attribution 4.0 International License  
 Copyright © 2020 –UPJOHNS