

## Case Report

### Pleomorphic adenoma of the cheek: an uncommon entity

<b>Volume : 6   Issue : 02   December 2018 • ISSN No 2321-3450   Page: 38-41</b>	
<b>Date Received: 21.11.2018</b>	<b>Date Published: 02.12.2018</b>
<b>Review Process: Double blind Peer Reviewed by Editorial Board Members</b>	
<b>Authors</b>	
Srivastava A(1), Kanaujia SK(2), Kaushik S(2), Malhotra R(2), Gautam H(3), Saxena N.(1) Assistant Professor(1), Professor(2) Associate Professor(3), GSVM Medical college, Kanpur, Uttar Pradesh	
<b>Corresponding author:</b> Dr. Amrita Srivastava Assistant Professor, Department of ENT Head Neck Surgery, GSVM Medical college, Kanpur, Uttar Pradesh. Email - dramritasrivastava@gmail.com	

#### ABSTRACT

We are presenting a rare case of Pleomorphic adenoma cheek. A 60 year old female patient presented with a painless swelling in right cheek since 4 years. On examination a well circumscribed, soft to firm 1.5x1cm mass was palpable. FNAC revealed Pleomorphic adenoma. The diagnosis was confirmed by histopathological examination after excisional biopsy of tumor.

**KEYWORDS:** pleomorphic adenoma, cheek, minor salivary gland

## INTRODUCTION

Pleomorphic adenoma is the most common benign neoplasm of the salivary glands. It accounts for 63.3% of parotid tumors, 59.5% of submandibular tumors and 42.9% occur in minor salivary glands.

In minor glands, the majority of pleomorphic adenomas are found in the palate, the next most common site are the lips and the cheeks. (1) There is a female preponderance from 3<sup>rd</sup> to 5<sup>th</sup> decade. (2) It is generally a slow growing and painless tumor. (3) Histologically Pleomorphic adenoma comprises of cells with epithelial and mesenchymal differentiation. The treatment of choice is wide surgical excision. (4)

This is a rare case report of Pleomorphic adenoma with exclusivity in its location of presentation.

## CASE REPORT

A 60 years old female presented with a painless slow growing swelling over right cheek of 4 years duration. There was no history of trauma, bleeding, fever, abnormal salivation or any oral surgery.

Clinical examination revealed a 1.5cm x 1cm, firm, non-tender, non-fluctuant, non-pulsatile, non-reducible mobile mass in the right cheek. The skin over the swelling was normal with no localized increase in temperature. Intra oral examination was normal. (Figure 1)

## INVESTIGATIONS

Patient was subjected to hematological, radiological and cytopathological profile. Blood results were within normal range. **USG Neck** revealed well defined lobulated heterogenous hypoechoic lesion 14.4 x 11.3 x 13.5 mm. in right cheek with presence of internal vascularity and with no obvious cystic degeneration or any calcification. (Figure 2) **Microscopic examination** with Haematoxylin and Eosin stained section revealed cellular smear. There were large number of epithelial cells lying in tubules, clusters as well as scattered singly. These cells had round to oval nuclei with slight variation in size. There was moderate amount of cytoplasm with well-defined cell boundaries. Background showed chondromyxoid substance along with singly scattered population of plasmacytoid myoepithelial cells. There was no evidence of malignancy.

Based on clinico-radiological and histopathological features, the final diagnosis of Pleomorphic adenoma arising in minor salivary glands of cheek was established.

Surgical excision was done under GA via external incision over cheek about 2.5cm above the body of mandible and mass sent for HPE. (Figure 3) Post-surgical period was uneventful.

**HPE** revealed a mixed tumor with biphasic appearance. There was an intricate mixture of epithelial and stromal fragments consistent with Pleomorphic adenoma. (Figure 4)

The patient was followed up over period of 18 months with no recurrence.

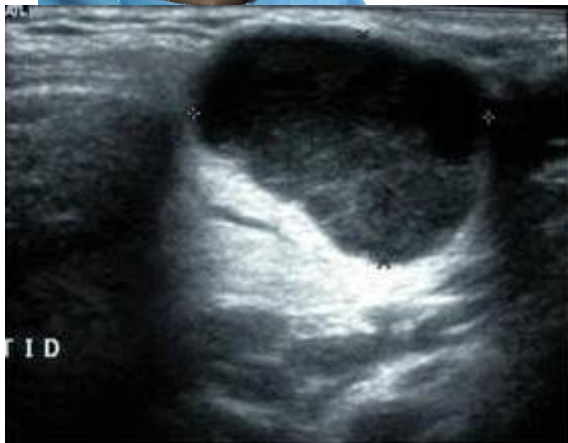
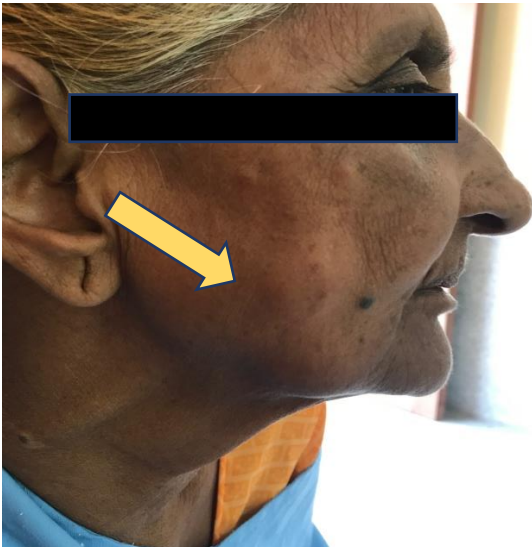
Figure1: Diffuse swelling of right cheek

Figure 2: USG showing hypoechoic mass

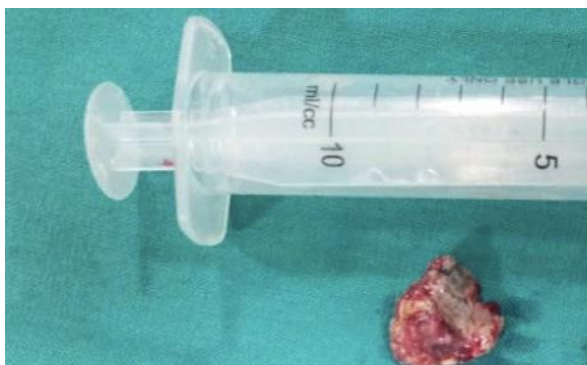

Figure 3: Gross specimen

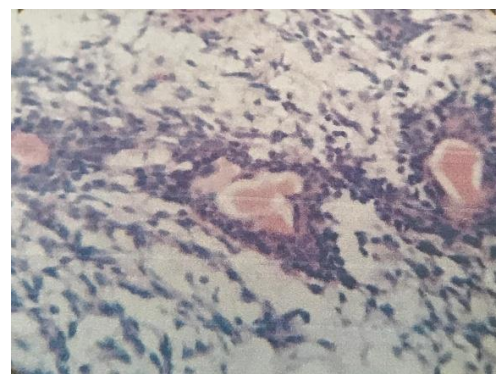


Fig 4: Histopathological finding

## DISCUSSION

Pleomorphic adenoma is the most common benign neoplasm of salivary glands. It is the most frequent tumor of the parotid gland comprising about 70% of the tumors of this organ. (5-8) Chidzonga MM, et. Al. studied the clinicopathology of 206 cases of Pleomorphic adenoma in Zimbabwe which showed anatomic distribution of this neoplasm. The parotid gland was most frequently affected in 39.8% of the cases. Among the minor salivary gland cheek was affected only in 4.4% of cases. (8) Yamamoto et Al reported a 9-year-old Japanese girl with pleomorphic adenoma of the cheek mucosa. (9) Cohen and Kronenberg reported two cases of juvenile pleomorphic adenomas of the cheek. (10-11)

Pleomorphic adenoma occurs more frequently in women than in men with the mean age of presentation as 4<sup>th</sup> decade. (12-14) In 2002, Jansisyanont et al., suggested that a total of 80 minor salivary gland tumors were identified in 49 female patients and 31 male patients and the ratio range from 1.2:1 to 1.9:1. (15) In our case also the patient was female but the age of presentation was 6<sup>th</sup> decade.

Pleomorphic adenoma of minor salivary glands clinically present as painless, slow growing masses. The covering mucosa is seldom affected unless it is secondarily traumatized. The findings of the case presented here is in agreement with those of other investigators. (5-7)

The microscopic appearance is enormously varied. Pleomorphic adenoma or mixed tumour of salivary gland consists of epithelial elements in a matrix of mucoid, myxoid or chondroid tissue. The present case fulfils the criteria for microscopic diagnosis of Pleomorphic adenoma. These findings have been well documented by Yoshiaki Takai and Allison Mackay. (16)

## **CONCLUSION**

Pleomorphic adenoma of cheek is a rare neoplasm and hence its diagnosis requires high index of suspicion. Pleomorphic adenoma should always be considered in differential diagnosis of cheek masses.

## **REFERENCES**

1. Michael Gleeson And Roderick Cawson. Benign salivary gland tumours. In: Michael Gleeson, George G Browning, Martin J Burton, Ray Clarke, John Hibbert, ed(s). Scott-Brown's Otorhinolaryngology, Head and Neck Surgery. 7th edition, Volume 1. London. Edward Arnold Publishers Ltd. 2008. 2475-2476.
2. Rao PK, Shetty SR, Hegde D. Ectopic pleomorphic adenoma. N Am J Med Sci 2012;4:190-2.
3. Dalati T, Hussein MR. Juvenile pleomorphic adenoma of the cheek: A case report and review of literature. Diagn Pathol 2009;4:32.

4. Pons Vicente O, Almendros Marqués N, Berini Aytés L, Gay Escoda C. Minor salivary gland tumors: A clinicopathological study of 18 cases. *Med Oral Patol Oral Cir Bucal* 2008;13:E582-8.
5. Lucas RB. Pathology of tumours of oral tissues, 4th ed. Edinburgh: Churchill Livingstone, 298-9.
6. Shafer WG, Hine KM, Levy BM. A textbook of oral pathology 4th ed. Philadelphia: WB Saunders 1983, 235.
7. Waldron CA. Mixed tumour and myoepithelioma in : ELLIS GL, Auclair PL, Gnepp DR, eds. *Surgical Pathology of salivary glands*. Philadelphia: WB Saunders 1999:165-86.
8. Chidzonga MM, Lopez Perez VM, Portilla Alvarez AL. Pleomorphic adenoma of the salivary glands. Clinicopathologic study of 206 cases in Zimbabwe. *Oral Surg Oral Med Oral Pathol Oral Radiol Endod* 1995;79:747-9
9. Yamamoto H, Fukumoto M, Yamaguchi F, Sakata K, Oikawa T. Pleomorphic adenoma of the buccal gland in a child. *Int J Oral Maxillofac Surg* 1986;15:474-7.
10. Cohen MA. Pleomorphic adenoma of the cheek. *Int J Oral Maxillofac Surg* 1986;15:777-9.
11. Kronenberg J, Horowitz A, Creter D. Pleomorphic adenoma arising in accessory salivary tissue with constriction of Stensen's duct. *J Laryngol Otol*. 1988;102:382-3.
12. Van Heerden WF, Raubenheimer EJ. Intraoral salivary gland neoplasms: a retrospective study of seventy cases in an African population. *Oral Surg Oral Med Oral Pathol* 1991;71:579-82.
13. Wang D, Li Y, He H, Liu L, Wu L, He Z. Intraoral minor salivary gland tumors in a Chinese population: a retrospective study on 737 cases. *Oral Surg Oral Med Oral Pathol Oral Radiol Endod* 2007;104:94-100.
14. Jorge J, Pires FR, Alves FA, Perez DE, Kowalski LP, Lopes MA, Almeida OP. Juvenile intraoral pleomorphic adenoma: report of five cases and review of the literature. *Int J Oral Maxillofac Surg* 2002;31:273-5.
15. Jansisyanont P, Blanchaert RH Jr, Ord RA. Intraoral minor salivary gland neoplasm: A single institution experience of 80 cases. *Int J Oral Maxillofac Surg* 2002;31:257-61.
16. Yoshiaki Takai, Allison Mackay. Diagnostic criteria for neoplastic myoepithelial cells in pleomorphic adenoma and myoepitheliomas. *Oral Surg Oral Med Oral Pathol Oral Radiol Endod* 1995;79:330-41.